
This item was submitted to [Loughborough's Research Repository](#) by the author.
Items in Figshare are protected by copyright, with all rights reserved, unless otherwise indicated.

DBT interpretation training: findings from analysis of expert visual search behaviour [Poster]

PLEASE CITE THE PUBLISHED VERSION

<https://www.eusobi.org/congress/>

VERSION

VoR (Version of Record)

PUBLISHER STATEMENT

This work is made available according to the conditions of the Creative Commons Attribution-NonCommercial-NoDerivatives 4.0 International (CC BY-NC-ND 4.0) licence. Full details of this licence are available at: <https://creativecommons.org/licenses/by-nc-nd/4.0/>

LICENCE

CC BY-NC-ND 4.0

REPOSITORY RECORD

Dong, Leng, Yan Chen, Alastair G. Gale, and Daniella Bernardi. 2019. "DBT Interpretation Training: Findings from Analysis of Expert Visual Search Behaviour [poster]". figshare. <https://hdl.handle.net/2134/28258>.

DBT interpretation training: findings from analysis of expert visual search behaviour

Leng Dong¹, Yan Chen¹, Alastair Gale¹, Daniella Bernardi²

¹Loughborough University, UK; ²Trento Hospital, Italy

Abstract

Digital Breast Tomosynthesis (DBT) provides better detection of early signs of breast cancer than 2D mammography. However, delivering training on interpreting DBT images can be complex due to the dynamic image environment. DBT trainees may be able to improve their skills by learning from an experienced radiologist's visual search behaviour. In this pilot study an expert's eye movements were examined to identify potential key performance techniques.

Twenty previously reported DBT cases were examined by an expert radiologist using a Hologic workstation and the radiologist's preferred hanging protocol. A remote eye tracker was placed underneath the workstation monitors to record her visual search behaviour. The hanging protocol used initially displayed both prior and current cases in 2D format then the DBT and 2D views of each breast were examined.

Known case pathology was used to determine areas of interest (AOIs) around abnormality locations to carry out a location based analysis of the eye movement data. Analysis demonstrates that, for the 2D views, the expert spent an average of 6.6% of their time looking inside the AOIs with 93.4% of time examining areas outside the AOIs. In contrast, for the DBT views, the expert spent an average of 68.5% of time inside the AOIs compared to 31.5% outside the AOIs.

The results demonstrate that the expert tended to visually scan the 2D view to locate potential suspicious areas and then used the DBT view to examine these sites in detail. Monitoring visual inspection behaviour of an expert during DBT interpretation yields insight into understanding their performance.

Introduction

Digital Breast Tomosynthesis has been proven to be superior to 2D mammography in many aspects. However, it is still under investigation whether it is cost-effective to implement DBT into breast screening programmes. It was reported by previous studies that the DBT reading time is normally twice as long as reading traditional 2D mammography (Skaane, et al., 2013). Whilst DBT screening has been implemented in Italy for over 7 years and proven to be feasible (Bernardi, et al., 2017). The Italian radiologists have taken part in the breast screening programme and managed to cope with the workload and deliver reliable diagnostic accuracy at the same time. Examining the visual search behaviour from the experienced DBT screening radiologist may reveal the insight of the effective DBT interpreting strategy and help DBT trainees improve their skills. In this study, an experienced DBT radiologist from Italian screening programme was invited to take part in the observer performance study while her visual search behaviour data was collected and analysed to explore the potential optimized DBT interpretation pattern.

Method

Twenty pathology proven digital breast tomosynthesis malignant cases were collected as the test case set. All the cases have prior images and consist of both 2D or C-view together with DBT images. The case set were pre-loaded to the Hologic DBT Selenia workstation and shuffled in random order. The Smart Eye remote eye tracker was configured underneath the DBT workstation to record participants' eye movements and a scene camera was fixed on top of the monitor to track participants' hand movements during the experiment (Figure 1). Before the participant started examining the cases, she was briefed with an information sheet telling her to view a set of twenty DBT cases and the task was detecting the abnormal lesions and report the details of any features. Then she was instructed to calibrate the eye tracking system through a 4-point calibration process.

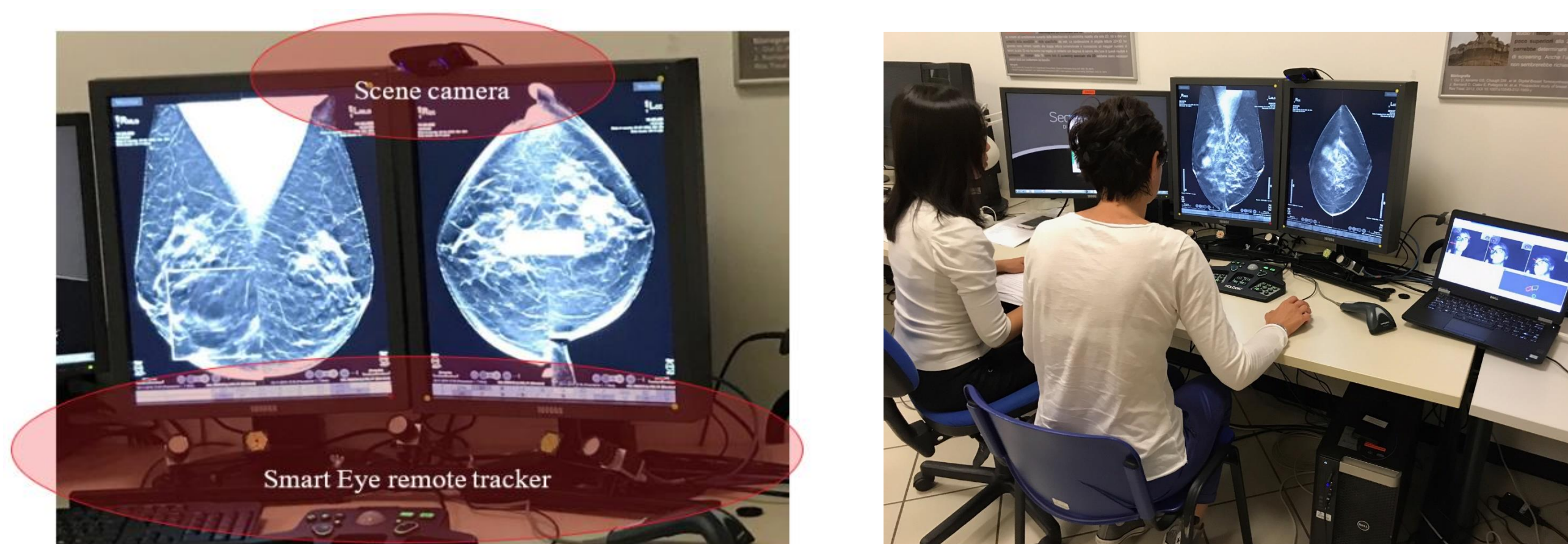

Figure 1. Left: Set up of eye tracking devices on the dual screen mammography workstation. Right: Participant is reading a DBT case while her eye movement data were collected.

The workflow of the DBT reading procedure is pre-set as the same as what has been used in the Italian screening programme which would allow participants to read the 2D/C-view first with prior images then go through each side of the breasts with the DBT view. Two training cases were also provided to help the participant grow familiar with the experimental set up. During the examining process, the participant was told to examine as she usually did during the screening tasks and when she made any decision, she needed to report the results verbally, and one of our experimental assistants would record her decision by marking the relevant answer on a reporting sheet. The participant needed to give a rating based on 5-point confidence level: Normal, Benign, Indeterminate, Suspicious and Highly suspicious. The location of the lesion was reported and type of feature was specified (Well defined mass, Ill Defined mass, Spiculate mass, Architectural Distortion, Asymmetry, Suspicious Calcification, Benign Calcification or Other features). After the participant finished the test, she was asked to fill in a questionnaire asking for information about years of experience on reading DBT images, how many DBT cases they read per month and any issues about the specific cases used here.

Results

The participant read the cases as an initial 2D overview followed by DBT views. The working flow of the DBT examination consists of comprehensive hanging layout of each side of the breasts in the following order: 2D-MLO/DBT-MLO/DBT-CC/2D-CC. Figure 2 shows a sample case with a pathology proven malignant lesion on the right side of the breast which is marked by yellow circles on different breast views. The participant's eye movements are overlaid as blue lines depicting their gaze trail and a 'heatmap' with brighter areas representing longer visual attention. It can be seen that the participant tended to perform an overall scanning over the 2D overview and managed to locate the lesion area (Figure 2.a). Then she switched to DBT views to further examine the details of the lesion on the right side of the breast (Figure 2.b). Moreover, on the left breast, which does not have a malignant lesion, the participant also visually examined large areas of the breast to see if any suspicious abnormality exists (Figure 2.c).

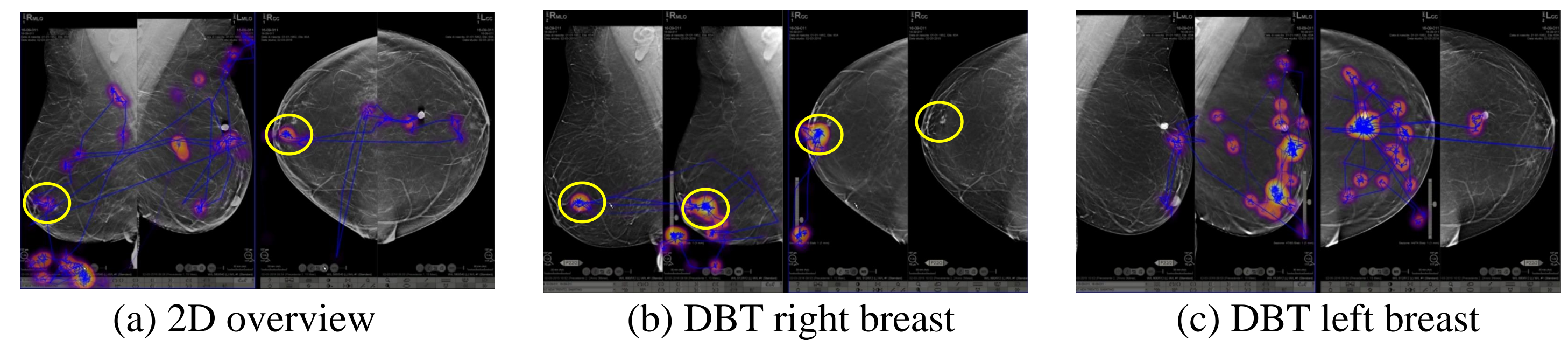


Figure 2. visualization of eye tracking data overlaying on a sample case with pathology known lesion on the right side of the breast (marked by yellow circle)

As the screen content was captured at the same time while the participant was examining the DBT cases, the DBT slice scrolling behaviour is extracted to inspect the relationship between visually examined slices and actual lesion thickness range. Figure 3 demonstrates the behaviour of DBT slice scrolling over the case reading time. The blue dashed line shows the known lesion boundary within the total cases slice range. The shadowed green areas depict the period of time when the certain view was visually examined. It can be seen that after the lesion range was first scrolled through, the participant spent most of time examining within the range of lesion boundaries.

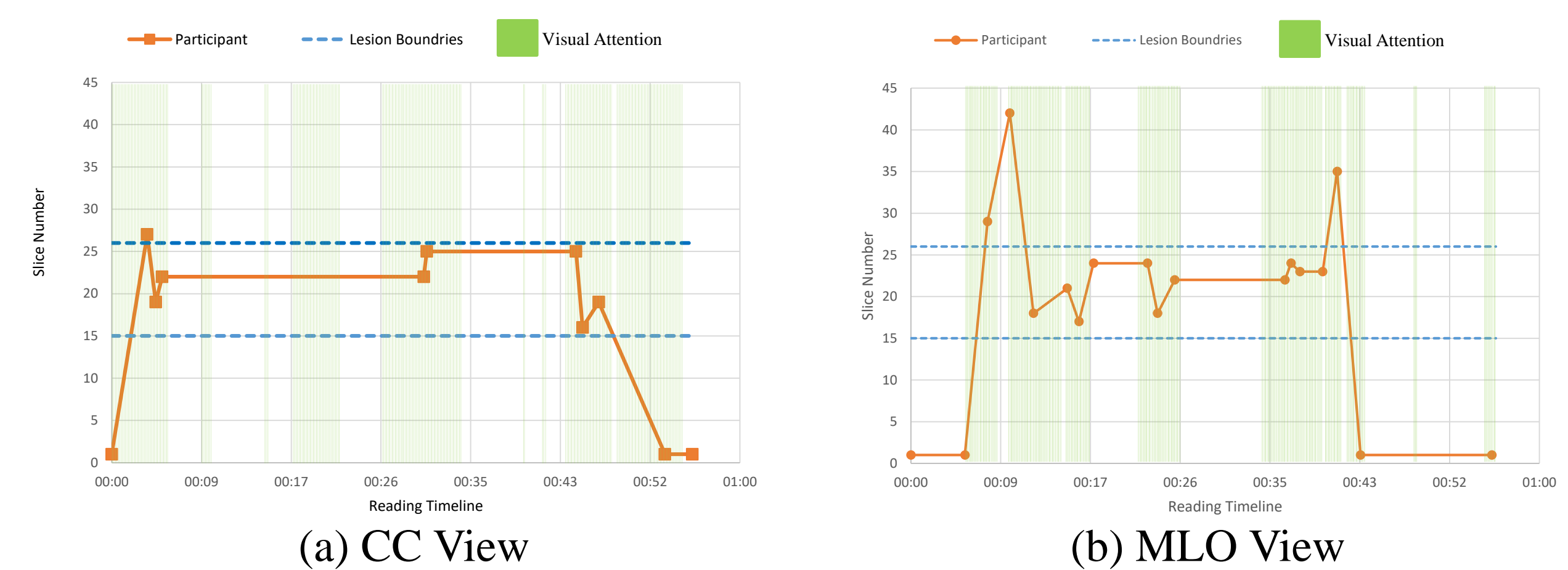


Figure 3. Participant's slice scrolling behaviour over reading time when a case with lesion range of 15-26 was examined

To further examine the difference of the visual search behaviour between 2D and DBT reading manner, the eye movement parameters were analysed. Current data analysis suggests that the expert spent longer time on the 3D views (86.47%) than the 2D views (13.53%) (Figure 4. a). For each case, the participant switched an average of 3.75 times between 2D and 3D views and 2.25 times between MLO and CC views (Figure 4. b). The lesion area of interest (AOI) analysis shows that for the 2D views, the participant spent an average of 6.6% of her time looking inside the AOIs with 93.4% of time examining areas outside the AOIs. In contrast, for the DBT views, the participant spent an average of 68.5% of time inside the AOIs compared to 31.5% outside the AOIs (Figure 4. c).

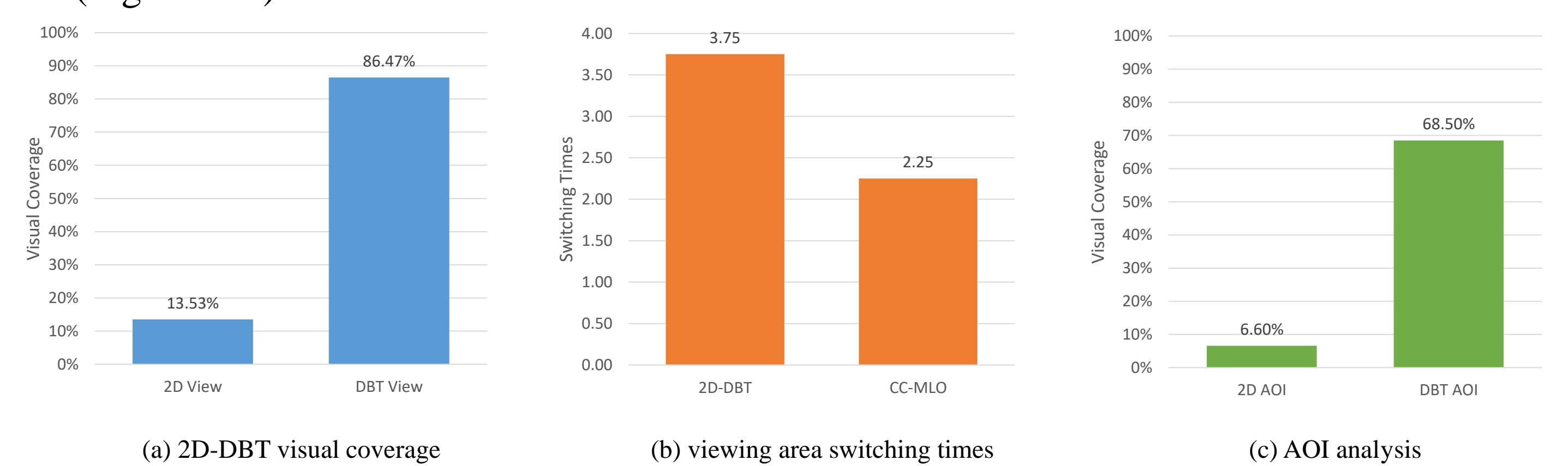


Figure 4. Eye movement parameters analysis

Conclusion

Examination of visual search behaviour from experienced DBT screening radiologists may reveal insight of how experts read DBT cases. This pilot study proposed several approaches to visualize and analyse DBT interpretation behaviour. This may help DBT trainees to learn a more effective reading strategy. More experiments and analysis are currently undergoing to extend these findings.

Acknowledgement

This study is supported by Hologic.

Contact

y.chen@lboro.ac.uk

References

- Bernardi, D., Belli, P., Benelli, E., Brancato, B., Bucchi, L., Calabrese, M., & Fedato, C. (2017). Digital breast tomosynthesis (DBT): recommendations from the Italian College of Breast Radiologists (ICBR) by the Italian Society of Medical Radiology. *La radiologia medica*, 1-8.
- Skaane, P., Bandos, A. I., Gullien, R., Eben, E. B., Ekseth, U., Haakenaasen, U., & Niklason, L. T. (2013). Comparison of digital mammography alone and digital mammography plus tomosynthesis in a population-based screening program. *Radiology*, 267(1), 47-56.